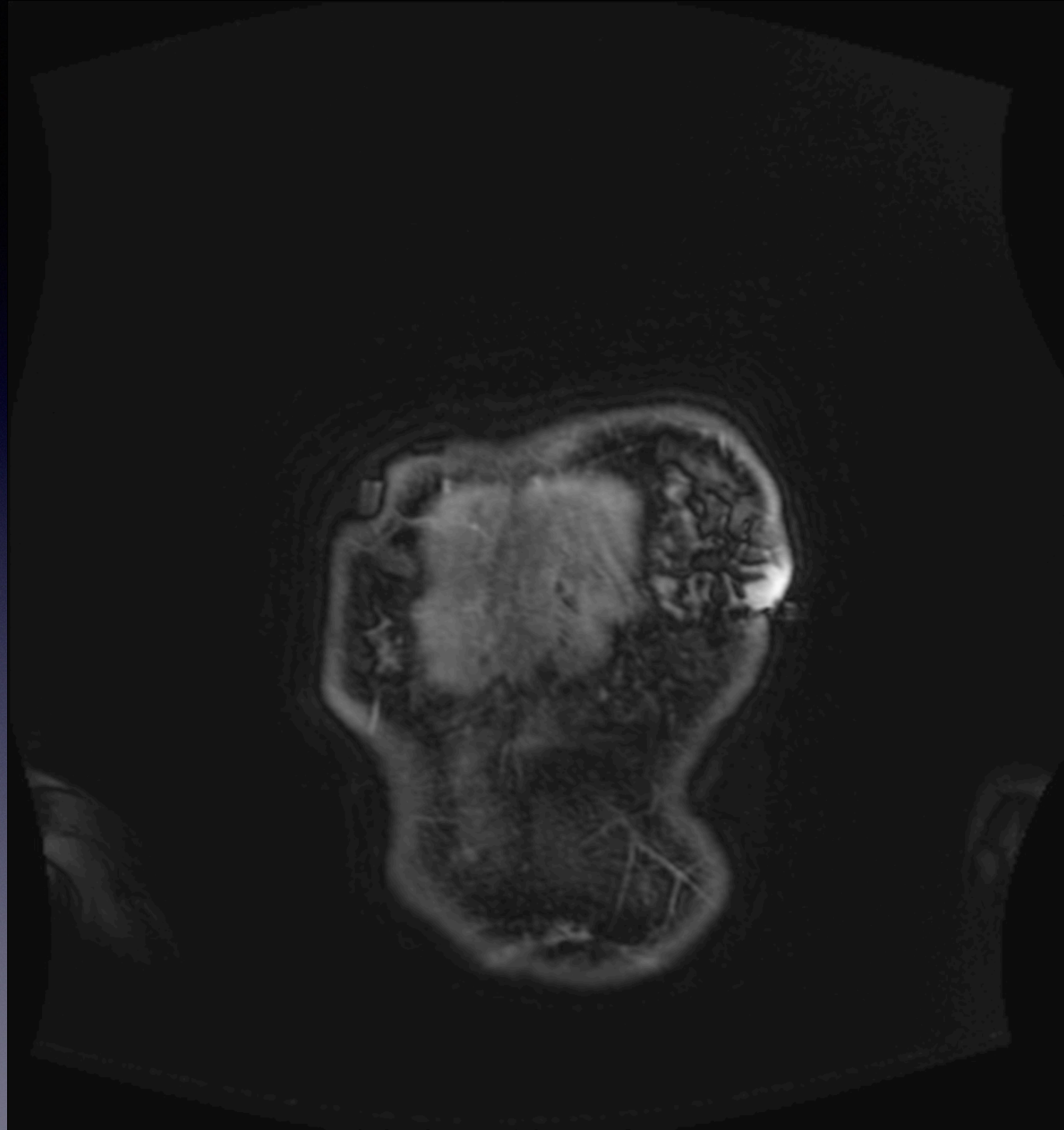



# IA & Physique des spins en Médecine

Pr Jean-Paul Vallée MD, PhD  
Radiologie HUG  
[jean-paul.vallee@hcuge.ch](mailto:jean-paul.vallee@hcuge.ch)







4.6s

# IRM cardiaque

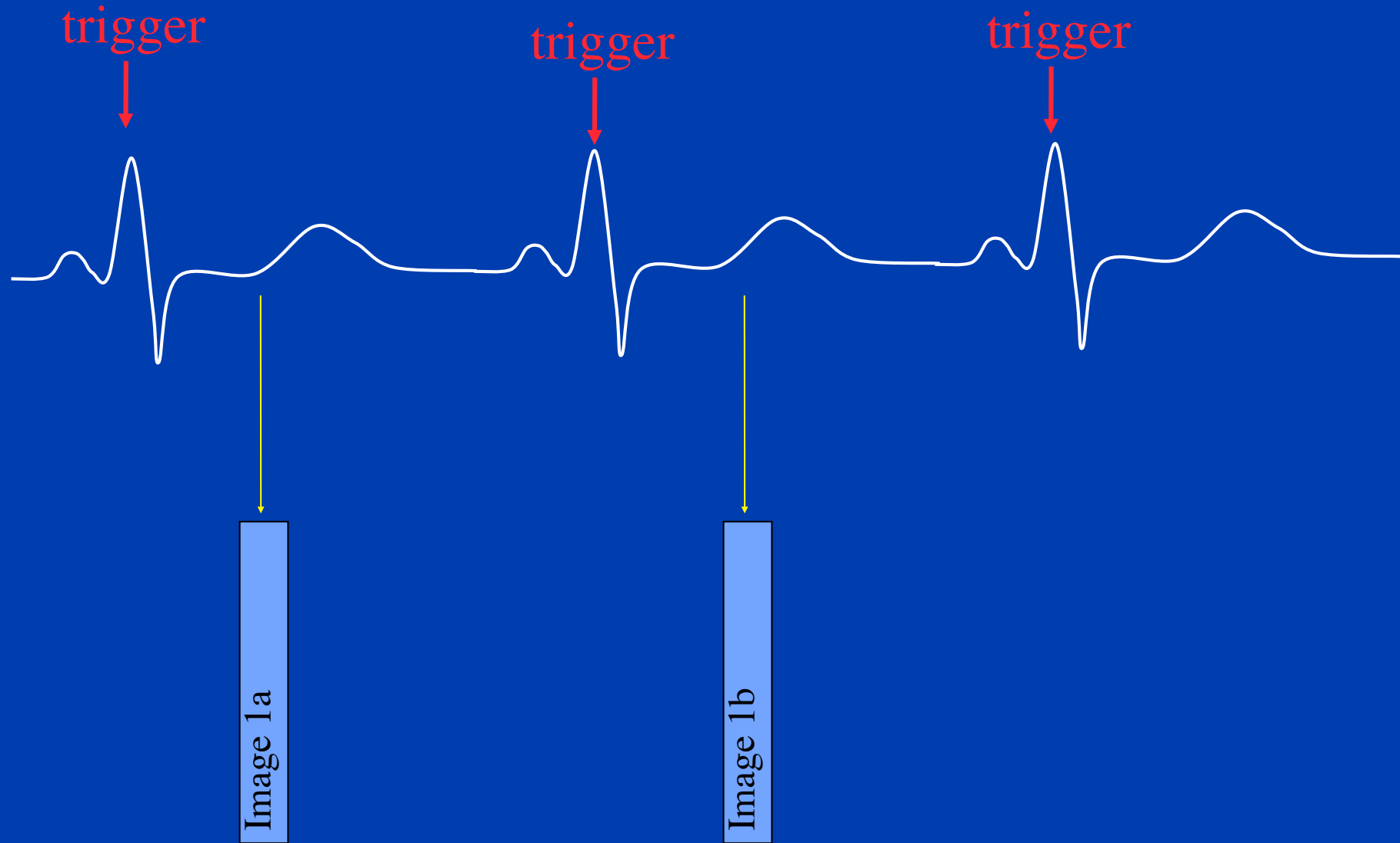
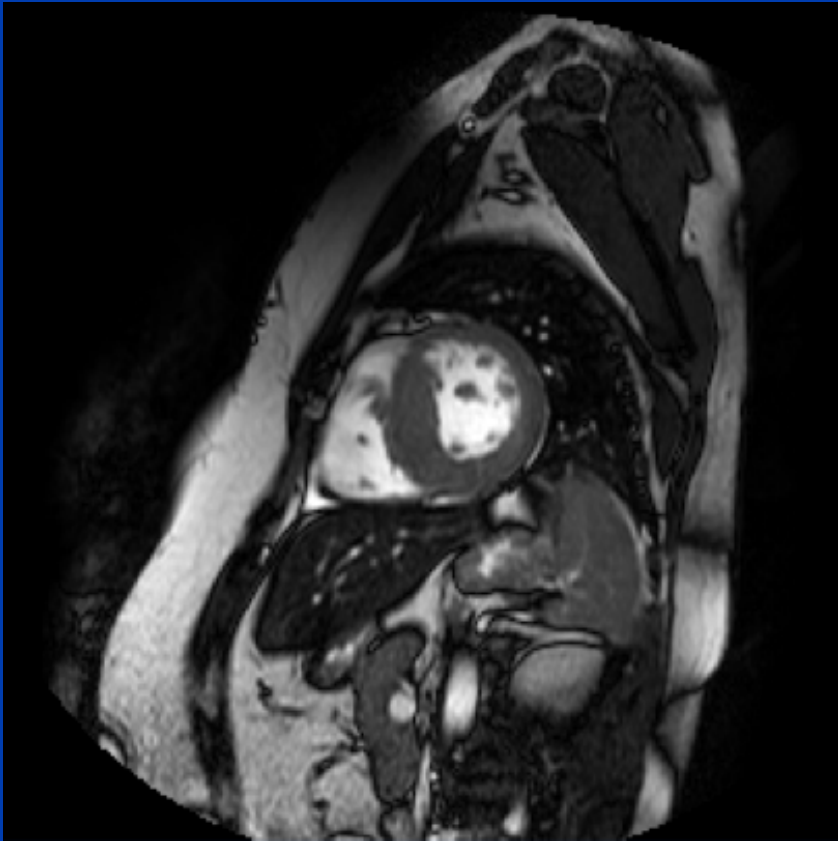


Image 1 = Image 1a + Image 1b +....

# Hypertrophic Obstructive Cardiomyopathy



IRM cardiaque

# Cine-MRI

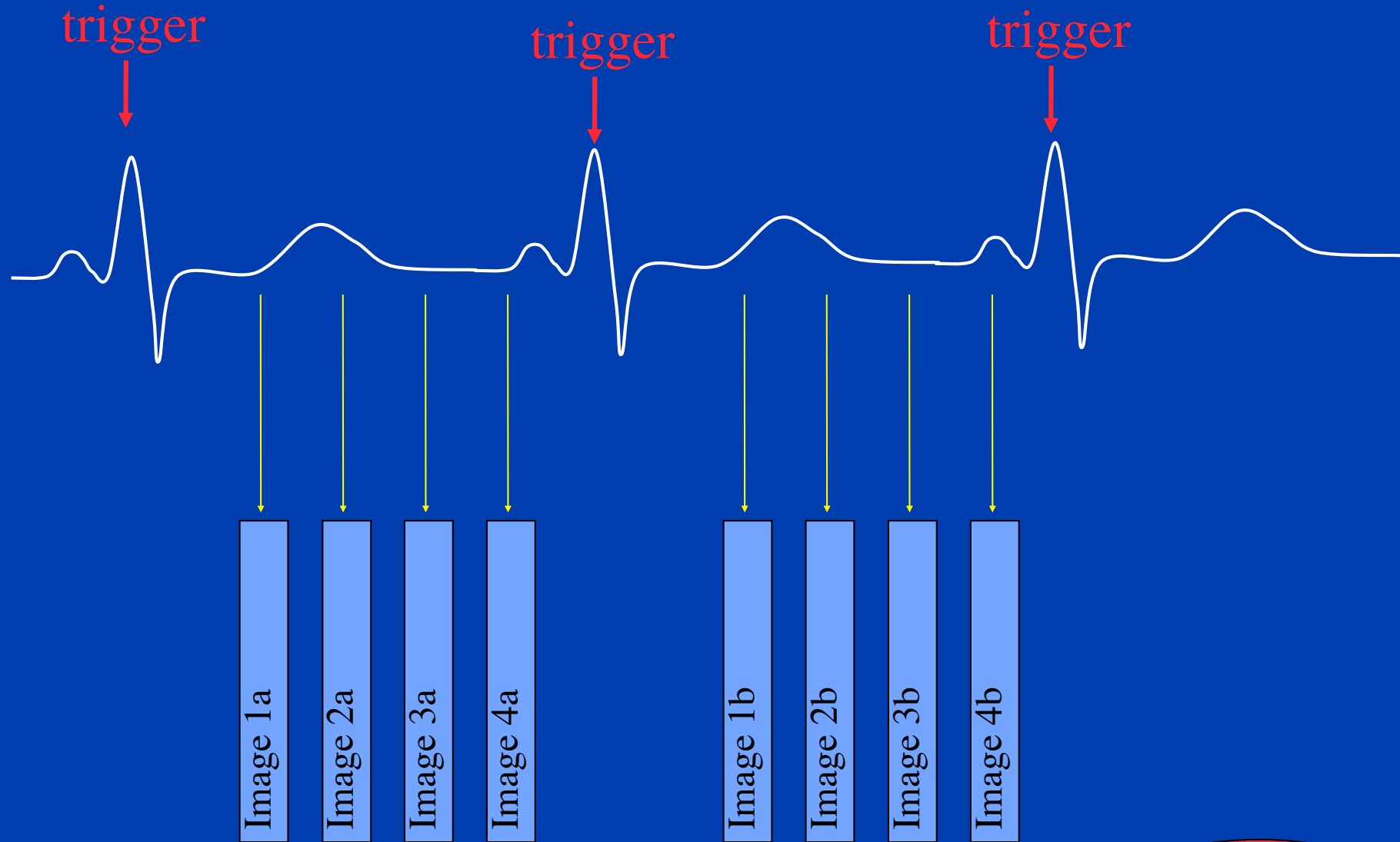
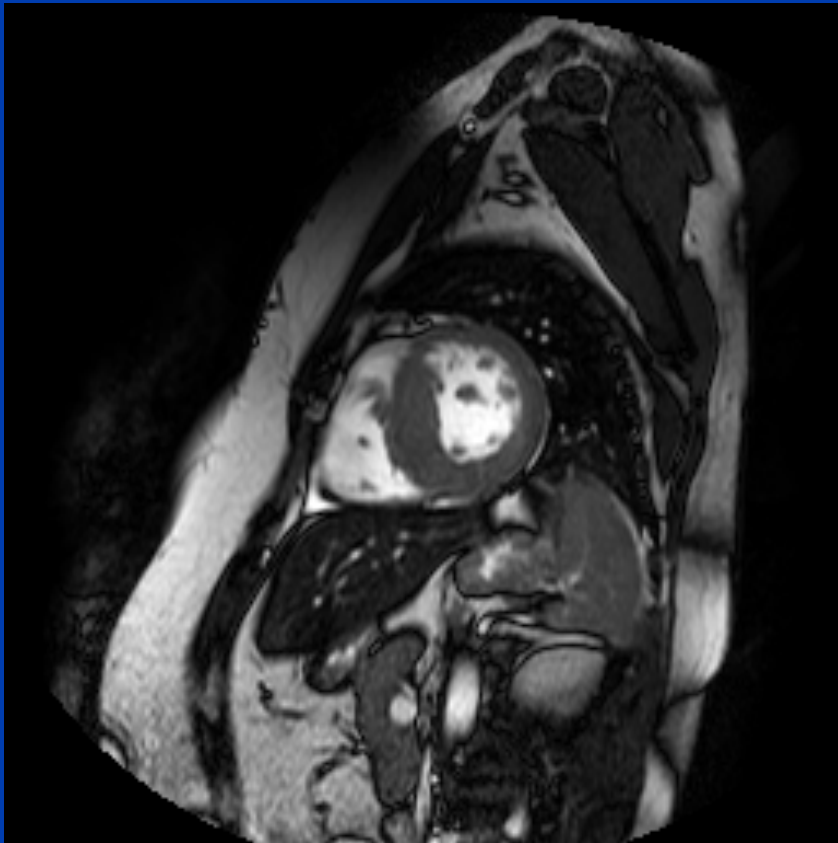


Image 1 = Image 1a + Image 1b +....

Image 2 = Image 2a + Image 2b +....

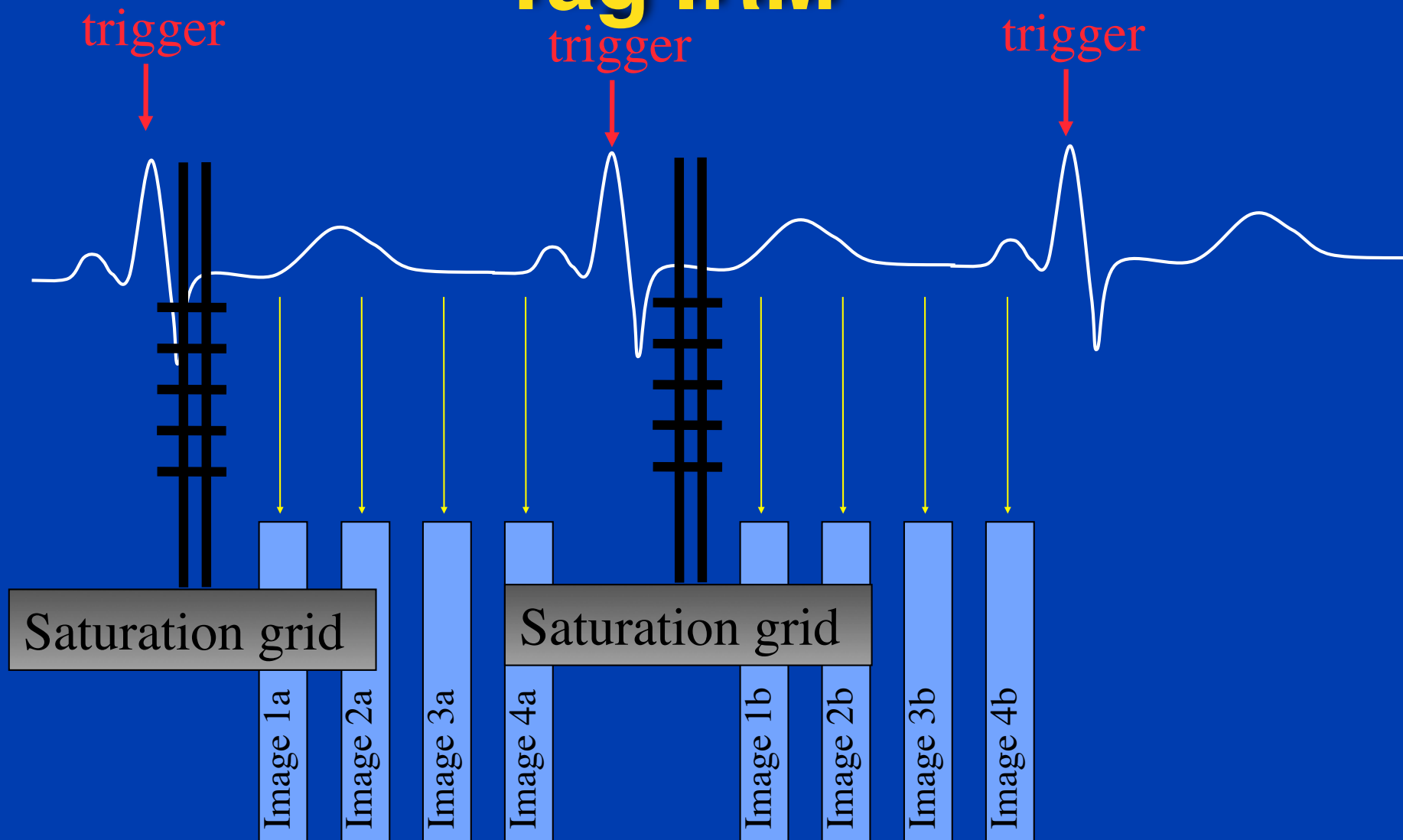
same location  
different cardiac phase

# Hypertrophic Obstructive Cardiomyopathy

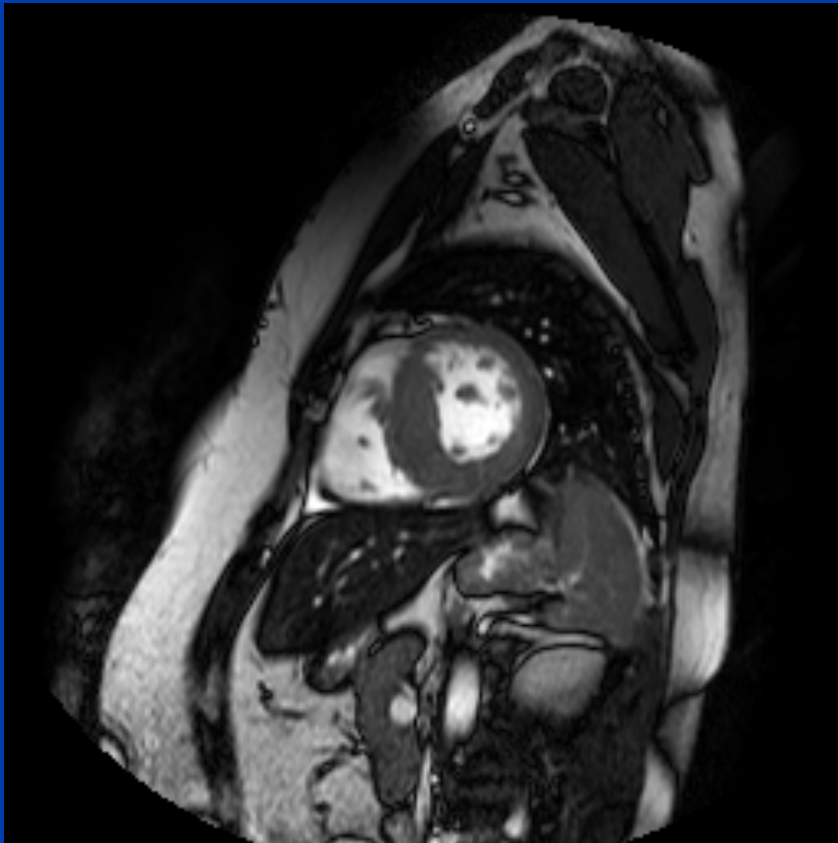


Cine MRI

# Tag IRM



# Hypertrophic Obstructive Cardiomyopathy



Cine MRI



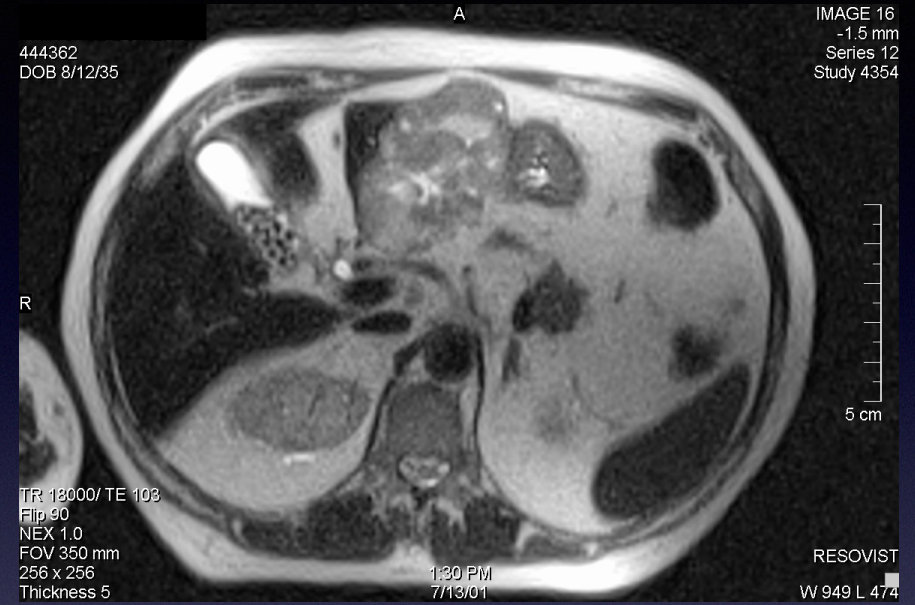
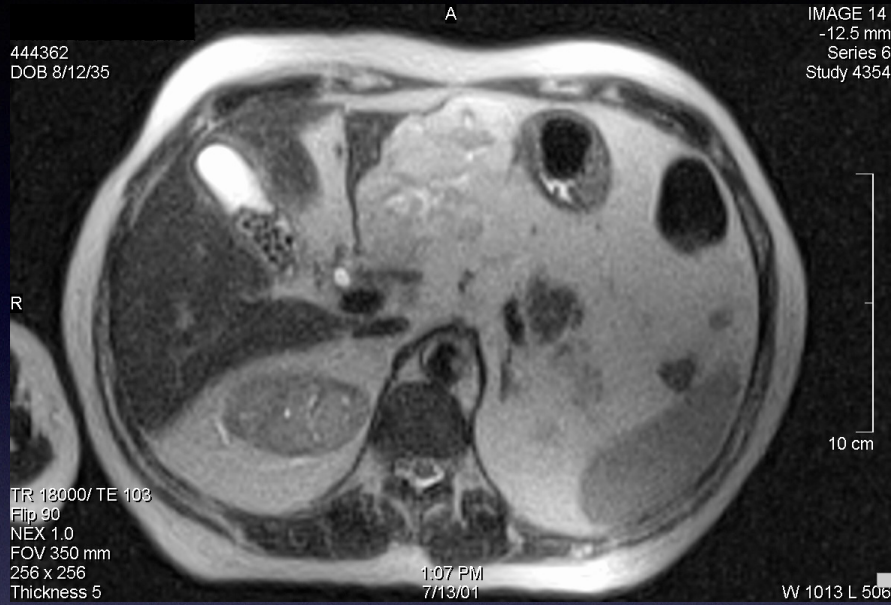
Tag MRI

# IRM hépatique I

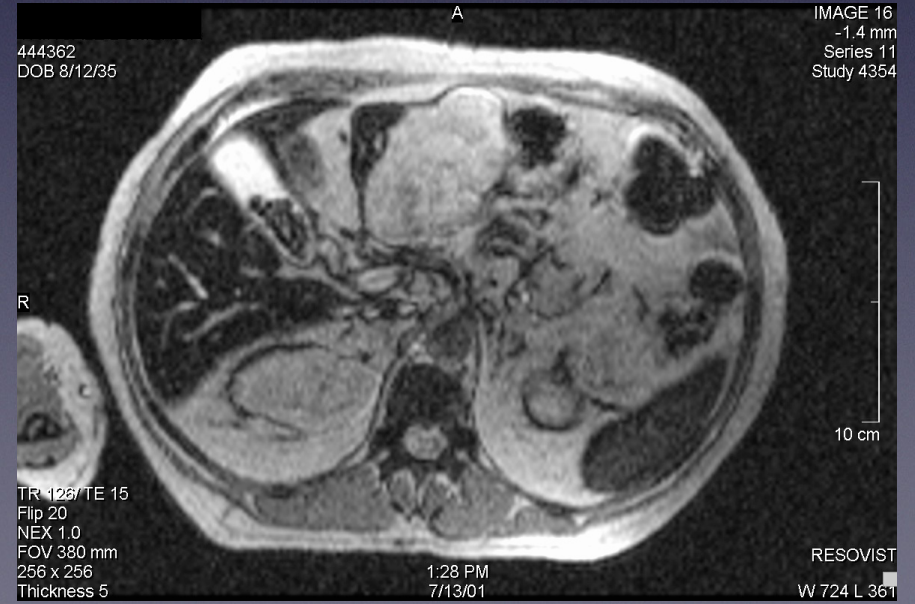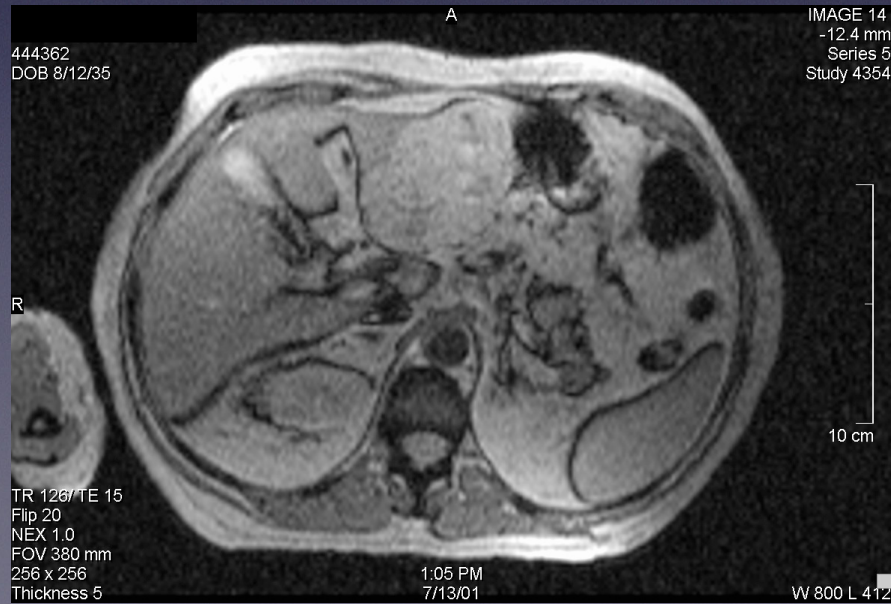Basal

Fer iv

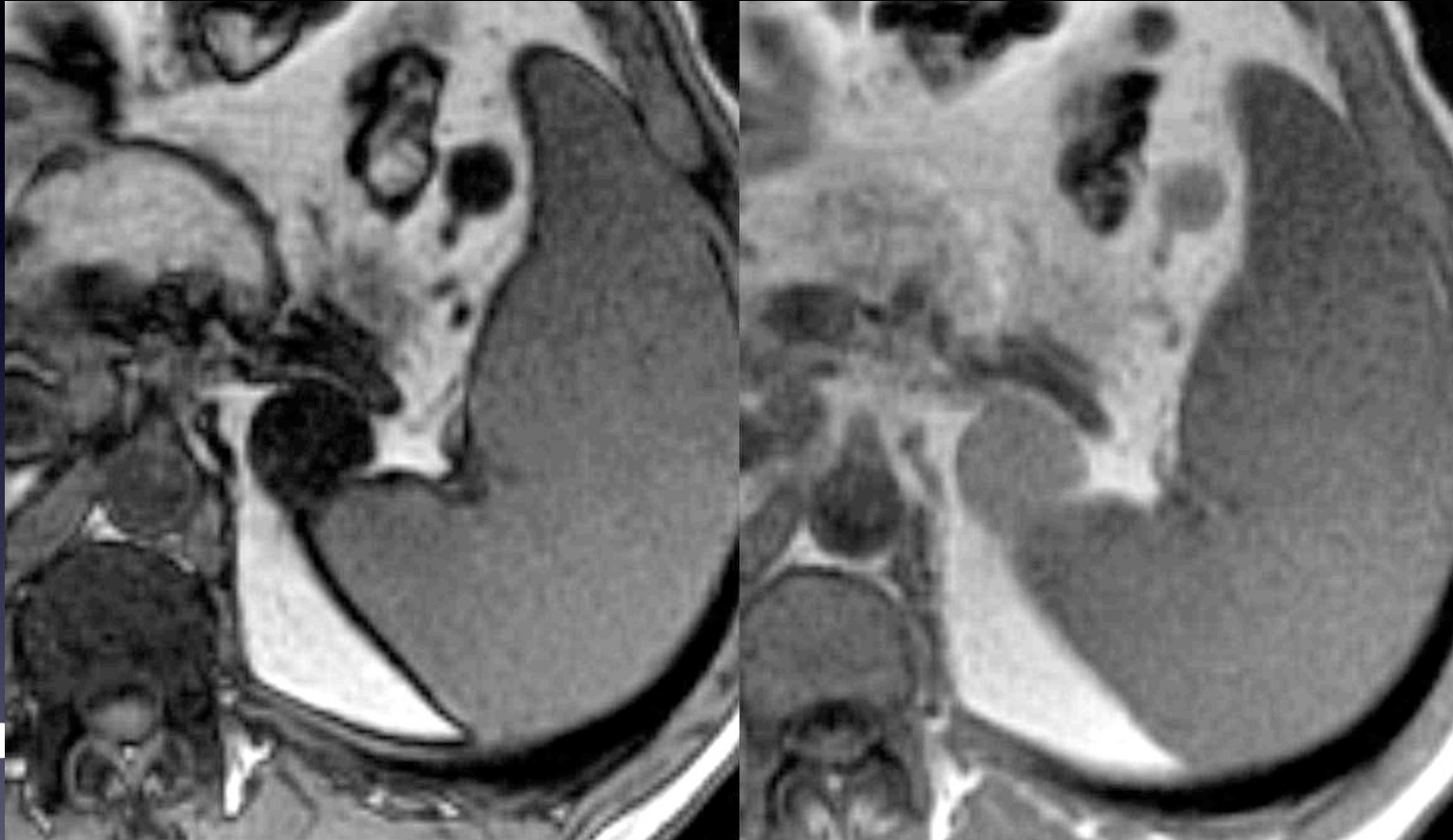
SE



GRE



# 2 séquences IRM en T1

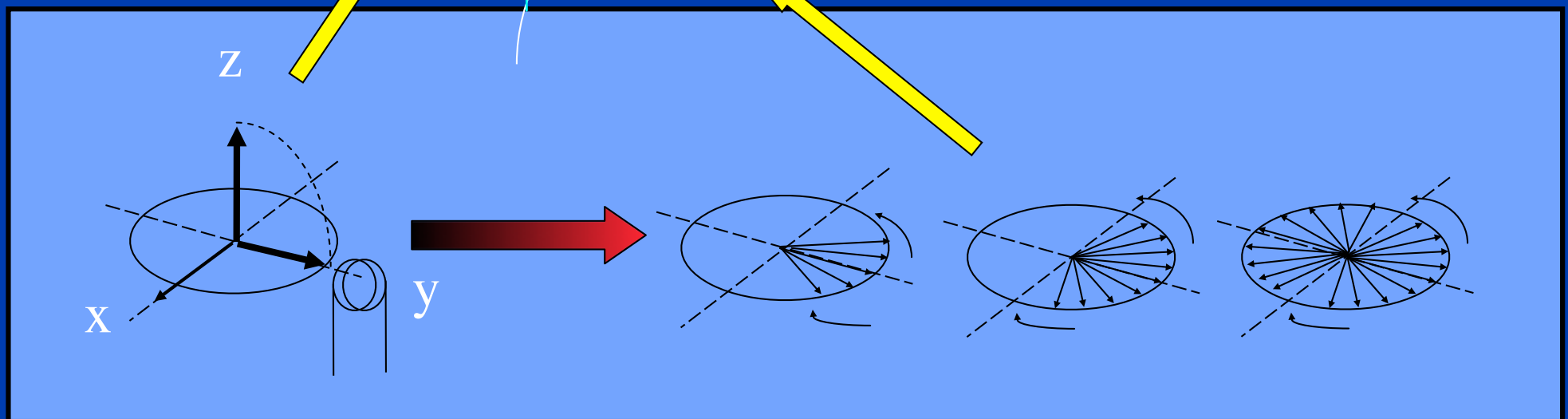
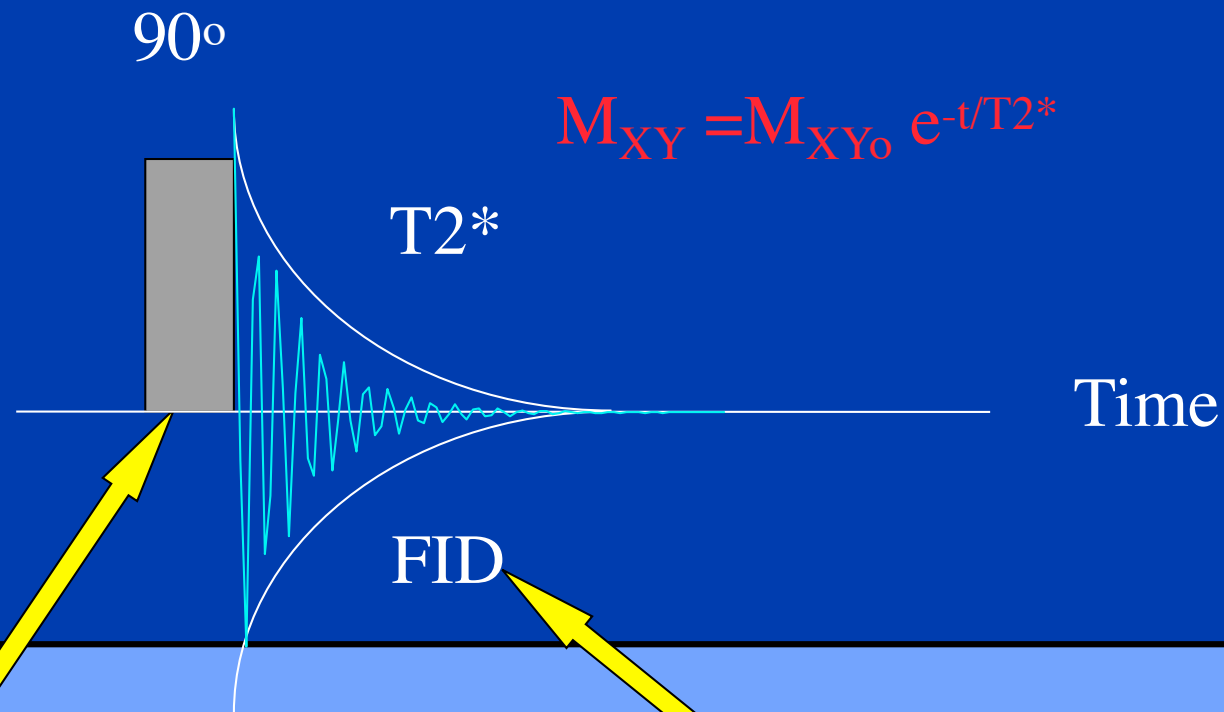


TE 2.3 ms

TE 4.6 ms

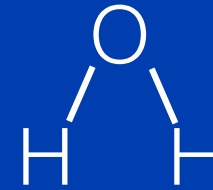TE = temps d'écho (durée entre l'excitation RF et l'enregistrement du signal)

# T2 relaxation

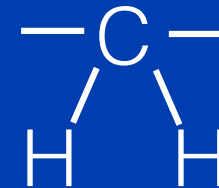


# T2 relaxation

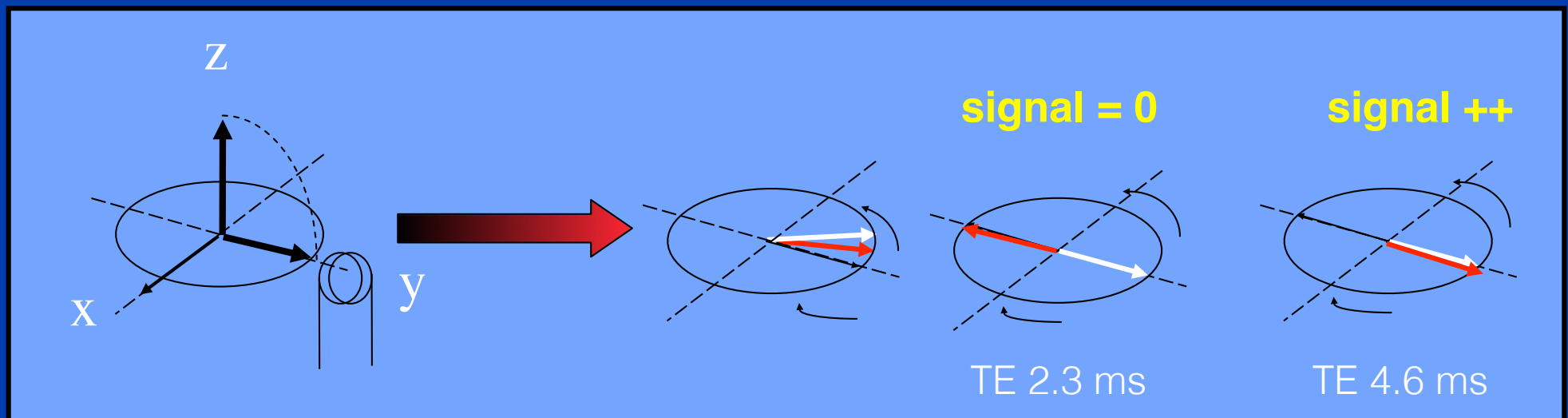
↑ = spin des protons de l'eau



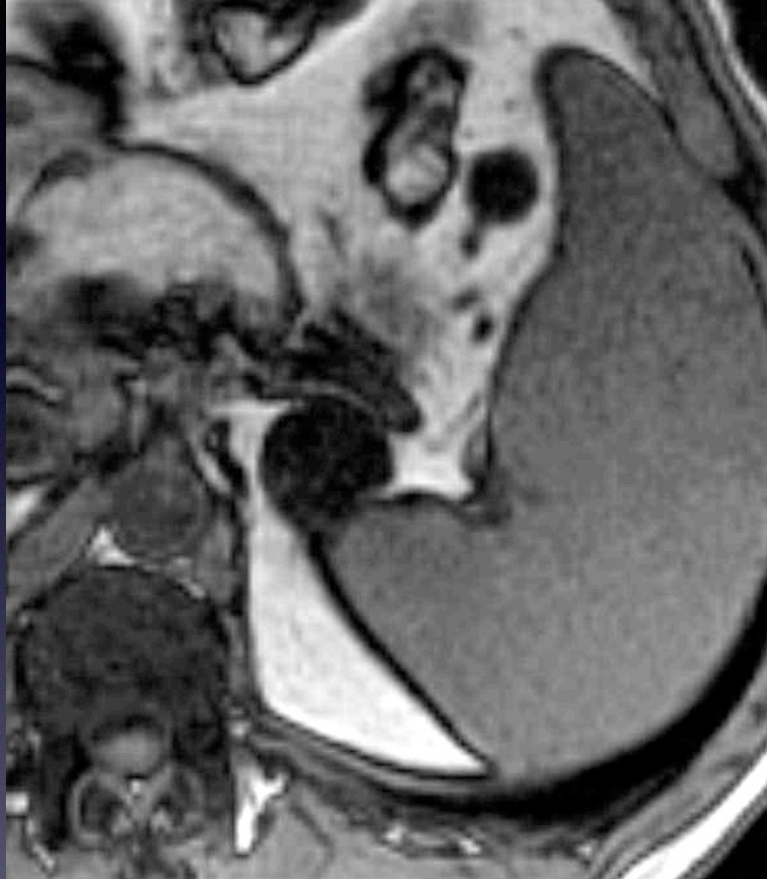↑ = spin des protons de la graisse



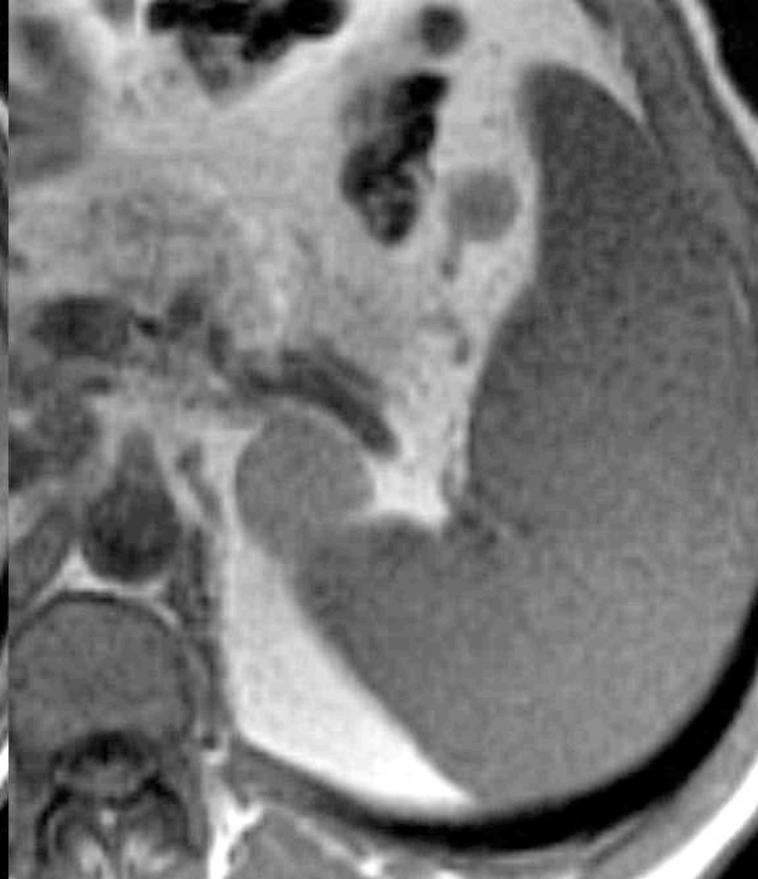Attraction du nuage électronique par O<sub>2</sub>  
=> Précession plus rapide de l'eau que de la graisse  
( $\Delta f = 224$  Hz et  $\Delta T = 4.6$  ms à 1.5T)



# 2 séquences IRM en T1

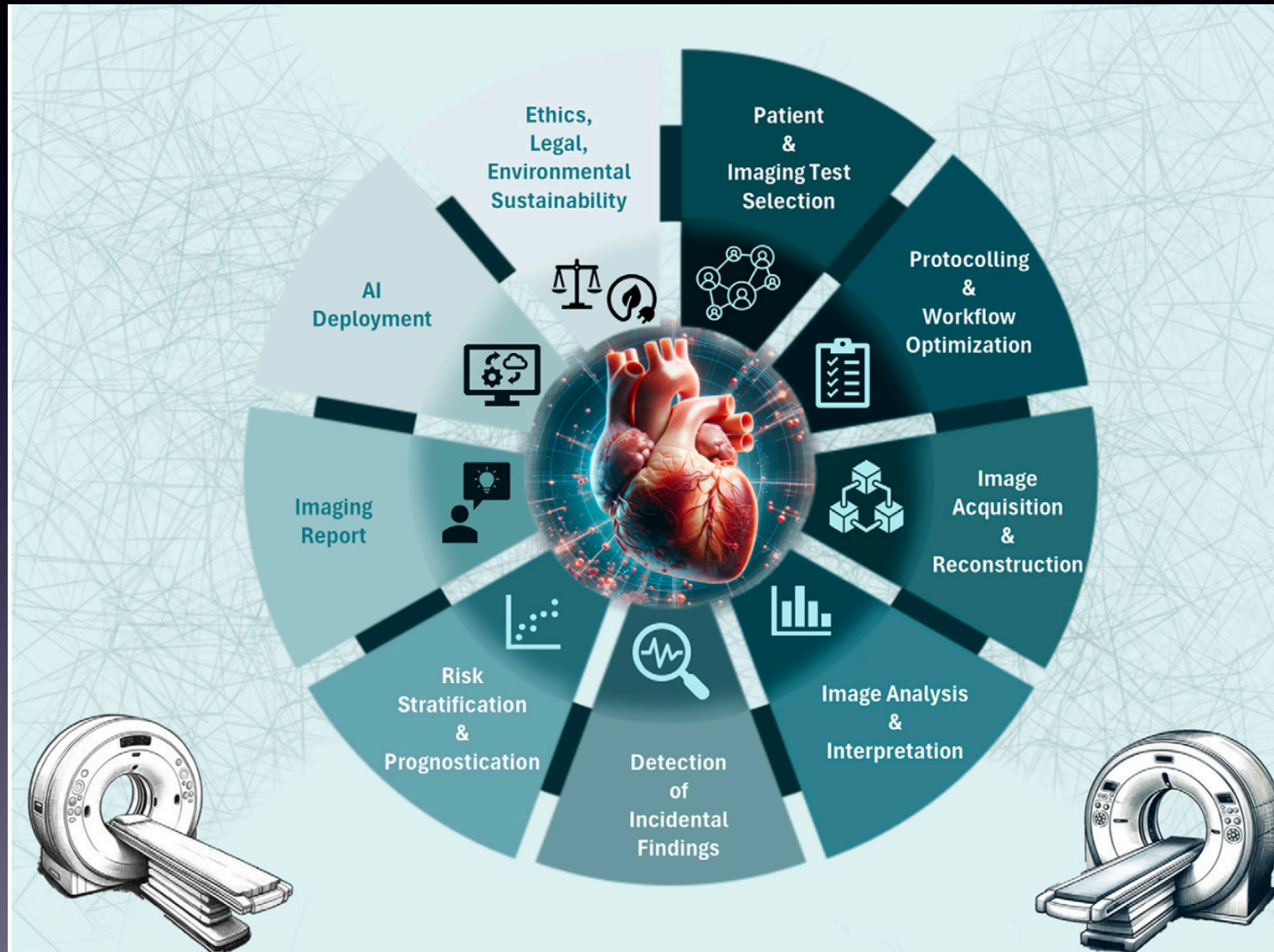


TE 2.3 ms  
Opposition de phase

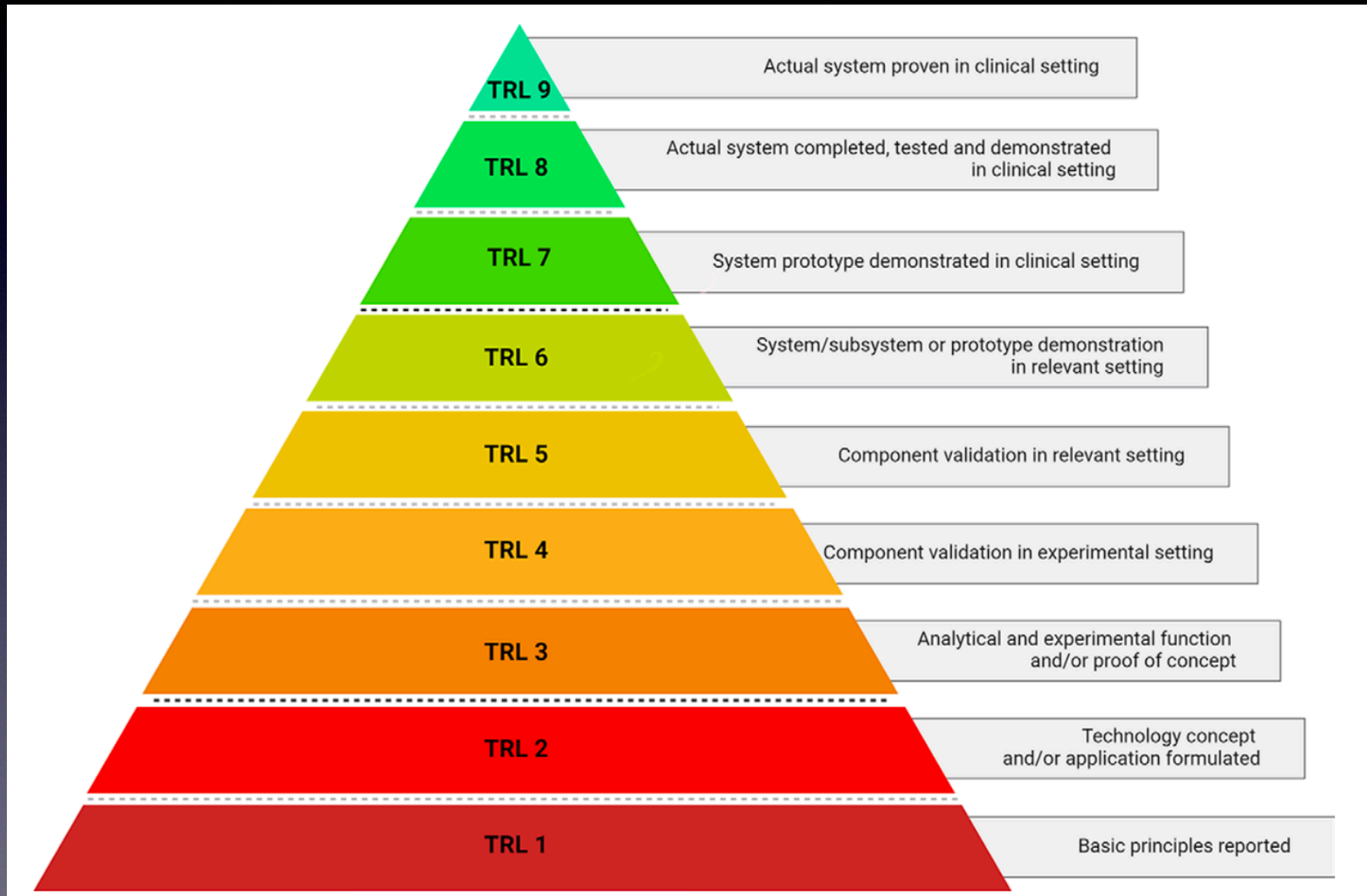


TE 4.6 ms  
En phase

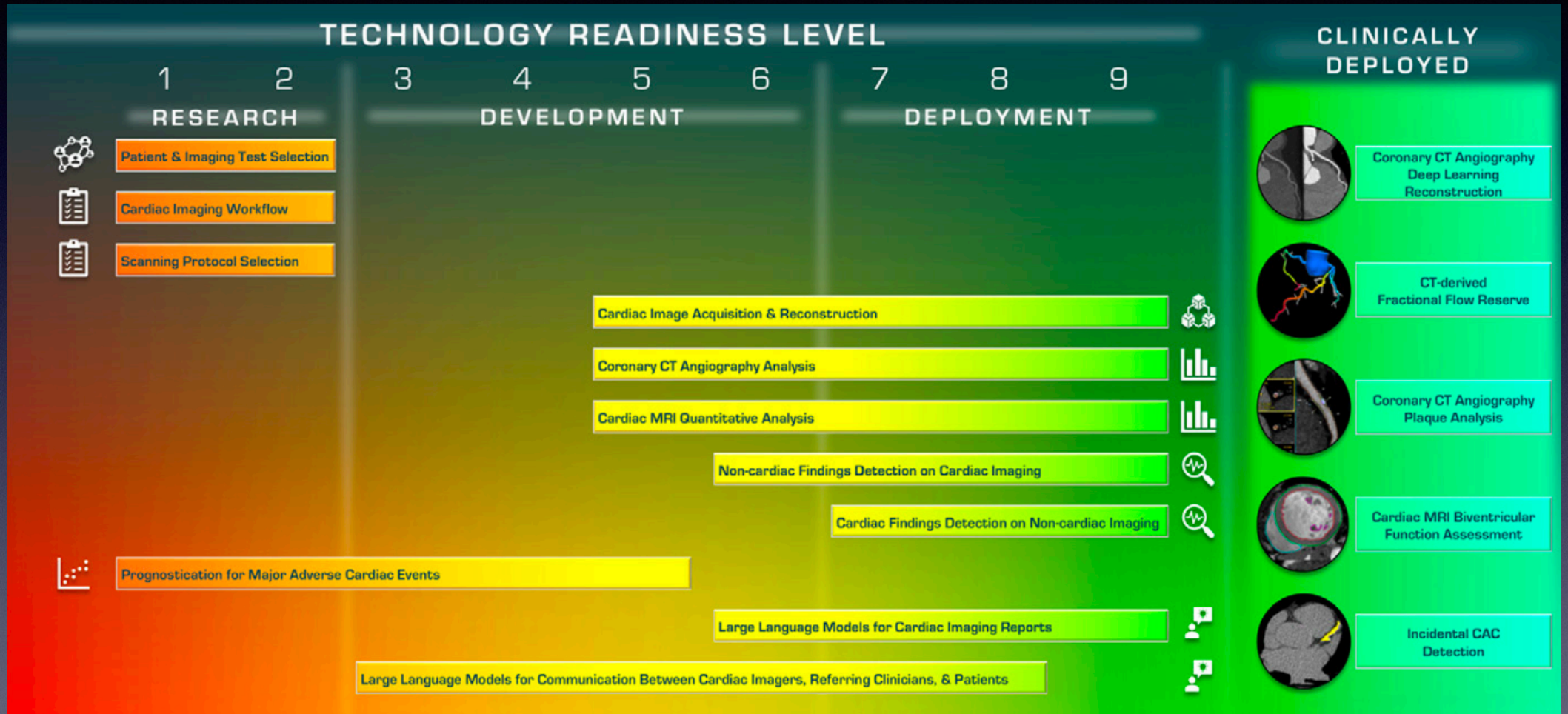
# IA en radiologie CVx



# IA en radiologie CVx



# IA en radiologie CVx



# Conclusions

- IA est outil
- La compréhension et la mémorisation restent indispensable pour la médecine
  - ➡ Bien apprendre l'anatomie
  - ➡ Bien comprendre la physique

Pour pour une démo de l'IRM: [jean-paul.vallee@hug.ch](mailto:jean-paul.vallee@hug.ch)

Merci pour votre  
attention!

Pour pour une démo de l'IRM: [jean-paul.vallee@hcuge.ch](mailto:jean-paul.vallee@hcuge.ch)